

Comparison of azithromycin and a combination of trypsin, chymotrypsin and papain proteolytic enzymes for the treatment of bovine cutaneous papillomatosis

Mehmet Zeki Yılmaz Deveci^{1*}

 0000-0002-9532-247X

Muhammed Enes Altuğ¹

 0000-0003-3896-9944

Halil Alakuş^{1*}

 0000-0001-9265-2310

Şule Yurdagül Özsoy²

 0000-0003-4254-7146

¹Hatay Mustafa Kemal University,
Faculty of Veterinary Medicine,
Department of Surgery,
Hatay, Turkey

²Adnan Menderes University,
Faculty of Veterinary Medicine,
Department of Pathology,
Aydın, Turkey

***Corresponding authors:**

Email address:

zekideveci@gmail.com

Abstract

Although various methods have been used in the treatment of bovine cutaneous papillomatosis (BCP), no definite treatment has yet been established. There are no studies regarding the efficacy of azithromycin (AZ) and of any combination of trypsin, chymotrypsin, and papain proteolytic enzymes (PEC) in the treatment of BCP. The objective of this study was to investigate the efficacy of AZ and PEC in the treatment of BCP. A total of 24 female Holstein cattle of 6-17 months of age with spontaneous BCP were used for this study. In addition to the clinical findings, the diagnosis was confirmed with histopathological examinations. The animals were divided at random into three groups (n = 8). The AZ group received 10 mg/kg/day PO for 10 days. In the PEC group, an injectable suspension of proteolytic enzymes was applied IM at 0.4 mL/10 kg dose, 3 times with 8-10 days interval and the spray was used topically once a day for 10 days. The control group (CO) was not treated. The mean in papilloma warts decreased 92.4 % in the AZ group, 83.38 % in the PEC group, and 59.48 % in the CO. There were statistically significant differences in warts presence decreases between the three groups (P < 0.05). Both AZ and PEC were considered successful for the BCP treatment. However, AZ was found more effective than PEC.

Keywords: cattle; herd; papillomavirus; skin; wart.

Submitted: 2020-06-30

Accepted: 2021-11-30

Published: 2022-06-16

Additional information and declarations
can be found on page 13

© Copyright 2022
Mehmet Zeki Yılmaz Deveci *et al.*

open access 



Distributed under Creative Commons CC-BY 4.0

Cite this as:

Deveci MZY, Altuğ Me, Alakuş S, Özsoy ŞY. Comparison of azithromycin and a combination of trypsin, chymotrypsin and papain proteolytic enzymes for the treatment of bovine cutaneous papillomatosis. *Veterinaria México OA*. 2022;9. doi: 10.22201/fmvz.24486760e.2022.888

Study contribution

As a contagious viral disease with a significant incidence in cattle, bovine cutaneous papillomatosis is an important problem in livestock production, which causes stress and yield losses in animals, and cost and labor losses to the farm. Although various methods have been used in the treatment, no definite treatment has yet been established to effectively reduce the economic losses associated with the disease. There are no studies regarding the efficacy of azithromycin and of any combination of trypsin, chymotrypsin, and papain proteolytic enzymes for bovine cutaneous papillomatosis treatment. In this study, both azithromycin and a combination of proteolytic enzymes were shown to be effective in the treatment. Additionally, based on this study, the use of azithromycin was found to be more effective than the combination of the mentioned proteolytic enzymes.

Introduction

Bovine cutaneous papillomatosis (BCP) is a viral infection with a significant incidence in cattle.⁽¹⁻³⁾ The lesions are located mainly in the head, neck and other body areas.^(1, 4) BCP cases cause stress and yield losses in animals and cost and labor losses to the farm. Another disadvantage is that it is contagious. For these reasons, it is an important problem in livestock production.^(5, 6) Finding more effective results in treatment, the labor and yield losses and thus economic losses may be reduced. In this context, the research continues in order to find more effective treatment strategies in the treatment of BCP cases.

Various methods have been used in the treatment of papillomatosis. Total or partial excision, ligature, and the autovaccination are common methods. Also, autohemotherapy, high-dose injection of local anesthetics in the bottom of the mass or intravenously, cauterization with certain substances (such as silver nitrate), cryotherapy, nonspecific immune system stimulants, drug applications such as anthiomalin, ivermectin, levamisole, tarantula cubensis, alkirom have been used as the method of treatment.⁽⁷⁻¹⁶⁾ Although various applications are currently in use, no single definite method or agent has yet been established for treatment.^(5, 7, 17, 18)

Azithromycin is an antibiotic in the macrolides group. It is an effective and well-tolerated drug of the azalide subclass and is used as an option in the treatment of human papillomatosis.^(19, 20) Moreover, azithromycin has been reported to be successful in the treatment of papillomatosis in dogs.⁽²⁰⁾ Since there is no research about it in cattle, the use of azithromycin was included in the hypothesis of this study.

Trypsin, chymotrypsin, and papain are proteolytic enzymes. Proteolytic enzymes are hydrolase enzymes that can be used for therapeutic purposes. They are used in the veterinary field for holistic or complementary treatment. Recently, studies with proteolytic enzymes in veterinary medicine are mostly directed to the treatment of mastitis and endometritis in ruminants.⁽²¹⁾ As a result of these studies; homeostasis control and regulation, local immunostimulation, necrotic and infected tissue residues and exudates elimination effects are indicated. It also has the ability to change the virulence of bacteria and viruses and has an immunomodulatory effect. Therefore, another essential element of the study is PEC (containing trypsin, chymotrypsin and papain). Although many agents or methods have been investigated

in BCP treatment, the research on the effects of PEC (trypsin, chymotrypsin, and papain) and azithromycin treatments was planned because of the lack of studies with these agents.

The aim of this study; a comparative study of the effect of PEC (containing trypsin, chymotrypsin and papain) and azithromycin, a macrolide antibiotic, in the treatment of spontaneous or idiopathic BCP cases.

Materials and methods

Ethical statement

The field study plan was approved by the Ethics Committee of Animals Experiments in the Hatay Mustafa Kemal University (decision no: E.1072).

Animals

A total of 24 female Holstein breed cattle with BCP spontaneously developed were used in the study. The animals weighed 220-340 kg (mean 291.67 kg) and have between 6-17 months of age. After the diagnosis was made by clinical examination, the definitive diagnosis was confirmed by histopathological examination.

Study design

The animals were randomly and evenly distributed ($n = 8$) as a negative control (CO) group, azithromycin treatment (AZ) group, and proteolytic enzyme combination treatment (PEC) group. No treatment was applied to the group CO and the patient's status and spontaneous changes were monitored. The azithromycin drug (Azeltin® Biofarma) in tablets was administered orally at a dose of 10 mg/kg for 10 days with 24-hour intervals to group AZ. The injectable suspension of the proteolytic enzyme combination (containing trypsin, chymotrypsin and papain) (NekroVeyxym® Ekomed) was administered intramuscularly to group PEC, three times at a dose of 0.4 mL/10 kg with 10-days intervals. The spray (SanditamPanazym-Zinc Spray® Veyx-Pharma), which also contains a combination of (trypsin, chymotrypsin, and papain) proteolytic enzymes, was applied locally once a day.

Clinical examination and blood analysis

The anamnesis of the animals and the age, gender and the breed information was obtained. The presence of lesions and warts was determined and monitored before and after treatment. Appetite, water intake and general clinical findings were also monitored.

For hematological examination, blood samples were taken for complete blood count before treatment, as well as 1 and 3 months after treatment. Blood samples were taken into EDTA tubes and complete blood counts were analyzed to evaluate WBC (White Blood Cell Count), RBC (Red Blood Cell Count), HGB (Hemoglobin), HCT (Hematocrit), MCV (Mean Cell Volume), MCH (Mean Corpuscular Hemoglobin), MCHC (Mean Corpuscular Hemoglobin Concentration) and RDW (Red Cell Distribution Width) values.

Histopathological examination

Excisional biopsy samples were taken for histopathological examination to confirm the definitive diagnosis. A blinded histopathological examination of the tissues was performed by a pathologist. After the tissue samples were fixed in 10 % neutral formaldehyde, routine tissue follow-up was performed. We took 5 µm-thick sections from paraffin blocks and stained with hematoxylin and eosin (H&E). Microscopic examination and microphotography were taken. The evaluations were done by taking into account the severity and extension of epidermal hyperplasia, acanthosis, degenerative changes, hyperkeratosis, inflammatory infiltration and vascular congestion. Thus, the diagnosis of BCP was confirmed by histopathological examination.

Statistical analysis

Differences in the number and the decrease ratios of warts were assessed using a Chi-square test. Significance was defined as $P < 0.05$.

Results

Clinical findings

Papilloma warts of varying numbers and diameters between 2-65 mm were determined in the neck, head, and eyes of the animals. Macroscopic examination revealed that the masses were almost black in color, hard, dry, rough and irregular, cauliflower-shaped, with or without stem. Only one animal had a pinkish color at the base of the papilloma warts. The number and proportions of BCP warts by location are given in [Table 1](#).

Changes in the number of wart counts and the decrease ratios of cases individually, before and after treatment are shown in [Table 2](#). Due to heterogeneous distribution, in the evaluation of the wart numbers, reduction rates (%) were calculated. The mean, standard deviation, median and range values in the numbers and in the decrease ratios of warts per treatment group are shown in [Table 3](#), before and after treatment. When the clinical findings after three months of follow up were compared, it was observed that warts completely disappeared in 75 % of animals in AZ group, 50 % in PEC group and 25 % in CO group. In the BCP-infected cattle, the general examination revealed normal appetite and no abnormality except the warts.

BCP diagnosis was confirmed by histopathological examination in all cases. One of the animals in the AZ group had transient cough and hyperthermia for a short period of time (1 d) during treatment, but this was thought to be due to non-treatment reasons. AZ and PEC groups showed no side effects during and after treatment. Pre- and post-treatment clinical appearance of AZ and PEC groups are presented in [Figures 1](#) and [2](#).

Table 1. Number and proportions of bovine cutaneous papillomas by location in the Holstein cows under study

Region	Count (n)	Percentage (%)
Eye and surroundings	63	33.51
Head	80	42.55
Neck	45	23.93

Table 2. Absolute frequency of warts across treatment days and decrease proportion of warts after 90 d under treatment per group of Holstein cows

Group ¹	Case code	Age (months)	Weight (kg)	Number of warts across days in treatment				Decrease in wart number after 90 d (%)
				0	30	60	90	
CO	CO1	13	270	13	15	5	1	92.3
	CO2	14	300	11	10	7	7	36.4
	CO3	14	300	10	6	2	1	90
	CO4	14	330	13	5	4	0	100
	CO5	15	300	2	2	3	2	0
	CO6	15	300	4	3	1	0	100
	CO7	13	300	3	4	3	3	0
	CO8	14	290	7	4	3	3	57.1
AZ	AZ1	14	300	10	13	6	3	70
	AZ2	13	320	13	17	16	4	69.2
	AZ3	15	340	11	10	4	0	100
	AZ4	15	300	3	4	0	0	100
	AZ5	17	330	9	2	1	0	100
	AZ6	15	270	4	0	0	0	100
	AZ7	13	290	5	12	4	0	100
	AZ8	14	240	4	4	0	0	100
PEC	PEC1	11	290	3	3	1	1	66.7
	PEC2	6	220	12	2	1	1	91.7
	PEC3	14	330	15	10	3	1	93.3
	PEC4	14	330	10	3	1	0	100
	PEC5	14	330	7	2	1	0	100
	PEC6	6	220	13	26	36	11	15.4
	PEC7	8	260	17	5	2	0	100
	PEC8	7	240	16	1	0	0	100

¹CO = control group; AZ = azithromycin group; PEC = proteolytic enzymes combination group.

Table 3. Mean, standard deviation (SD), median and range values in the number of warts across treatment days and decrease proportion of warts after 90 d per group of Holstein cows¹

Group ²	Value	Age (months)	Weight (kg)	Number of warts across days in treatment				Decrease in wart number after 90 d (%)
				0	30	60	90	
CO	Mean	14	298.8	7.9	6.1	3.5	2.1 ^a	59.5 ^a
	SD	0.8	16.4	4.5	4.3	1.9	2.3	42.9
	Median	14	300	8.5	4.5	3	1.5	73.6
	Range	13-15	270-330	2-13	2-15	0-7	0-7	0-100
AZ	Mean	14.5	298.8	7.4	7.8	3.9	0.9 ^b	92.4 ^b
	SD	1.3	32.7	3.8	6.1	5.4	1.6	14.1
	Median	14.5	300	7	7	2.5	0	100
	Range	13-17	240-340	3-13	0-17	0-16	0-4	69.2-100
PEC	Mean	10	277.5	11.6	6.5	5.6	1.75 ^b	83.4 ^c
	SD	3.7	48.9	4.8	8.4	12.3	3.8	29.7
	Median	9.5	275	12.5	3	1	0.5	96.7
	Range	6-14	240-330	3-17	1-26	0-36	0-11	15.4-100

¹Significant differences were found between CO, AZ and PEC groups (n: 8) in the third-month post-treatment wart count and wart count reduction percentages. Differences between different letters in the same column between the groups were statistically significant (SPSS, Chi-square test, $P < 0.05$).

²CO = control group; AZ = azithromycin group; PEC = proteolytic enzymes combination group.




Figure 1. Clinical presentation of papillomatosis in one animal from the AZ group before (a, b) and after (c, d) treatment.

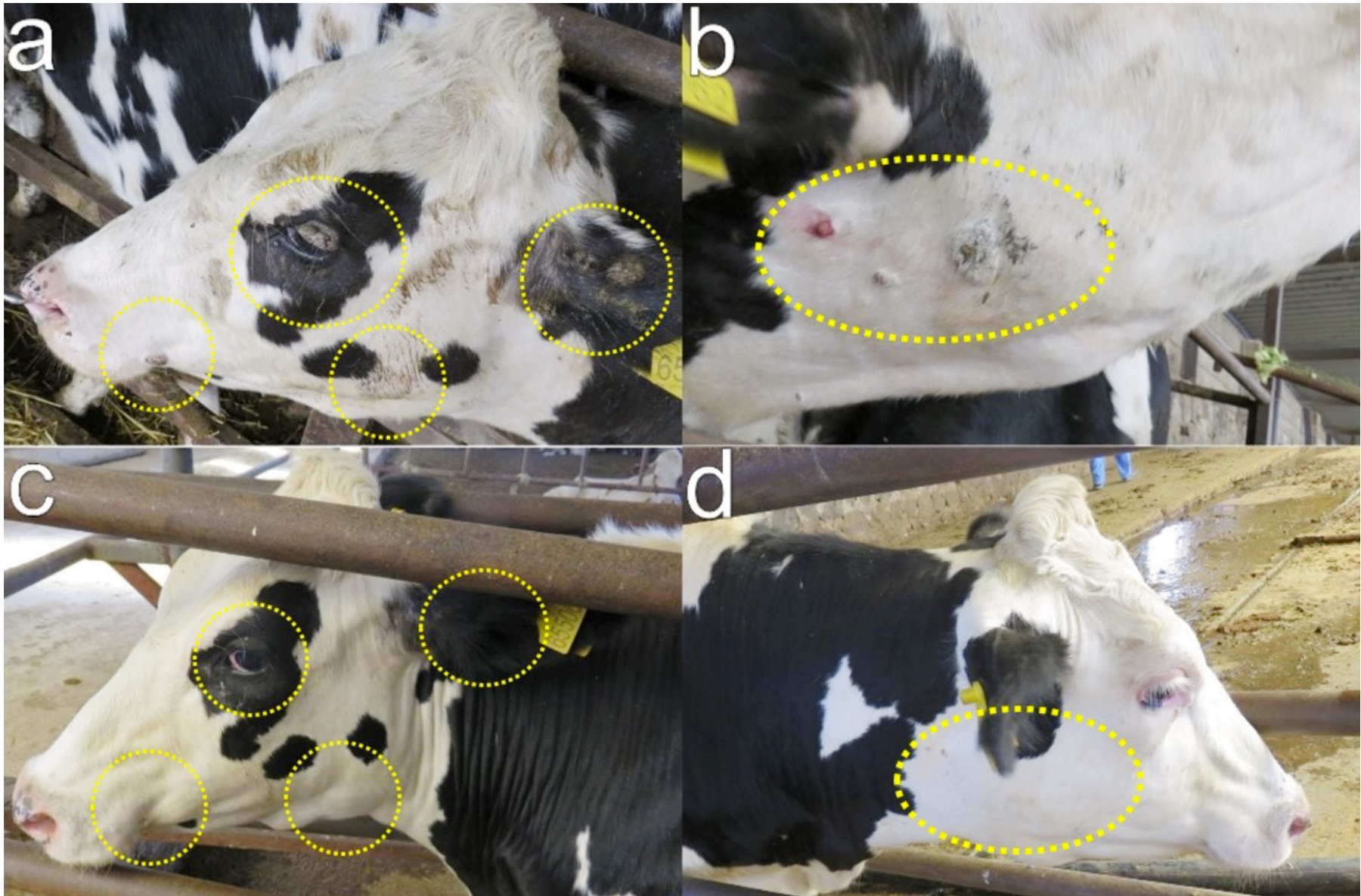


Figure 2. Clinical presentation of papillomatosis in one animal from the PEC group before (a, b) and after (c, d) treatment.

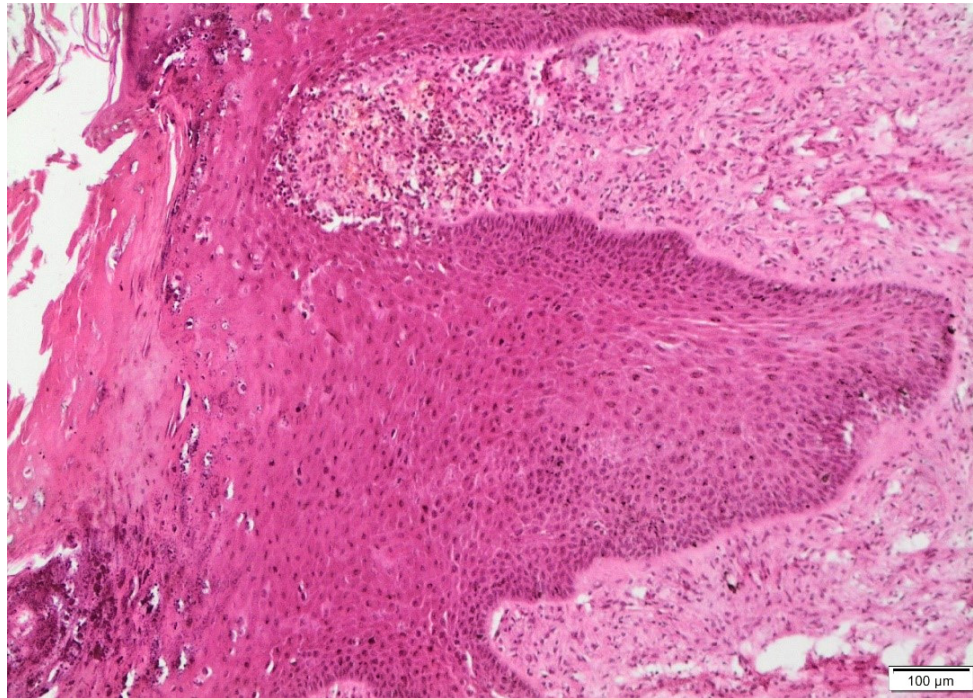


Figure 3. Hyperkeratosis, hyperplasia and acanthosis in epidermis cells of Holstein cows stained with hematoxylin and eosin (100 µm scale).

Complete blood count findings

There was no significant difference between the groups for the complete blood count analyses, which were within normal ranges: WBC (5 500-13 700 cells/µL), RBC ($4.8-7.3 \times 10^6$ µL), HGB (8.3-12.3 g/dL), HCT (22-35 %), MCV (37-51 fl), MCH (13-19 pg), MCHC (35-41 g/dL), and RDW (15-21 %).

Histopathological findings

Histopathological examination revealed various rates of hyperkeratosis, squamous epidermal cell thickening (hyperplasia) and papillary increase of stratum spinosum layer (acanthosis) in all tissue samples. There were degenerative changes in the epidermis, especially in granular cells, ranging from diffuse spongiosis and parenchyma to severe balloon degeneration. In addition, a large number of keratohyaline granules of various sizes were observed in the cytoplasm of keratinocytes.

Numerous open cytoplasmic vacuoles and cells with irregular, eccentric and hyperchromatic nuclei were noted in the stratum granulosum and spinosum layers. Significantly increased connective tissue (fibroblasts) was observed in the dermis as nested bundles and there were islets consisting of stratum spinosum cells between these enlarged connective tissue cells. In the dermis, hemorrhage and vascular hyperemia, mononuclear inflammatory cell infiltration that mostly consisted of lymphocytes, were observed.

The severe proliferation of connective tissue in the dermis was observed in some cases. Papillomatosis was confirmed by histopathological examination in all cases. In addition, 18 (75 %) of these masses were in characteristics of papillomas and 6 (25 %) of fibropapillomas. Three examples of histopathological images are presented in Figures 3, 4, and 5.

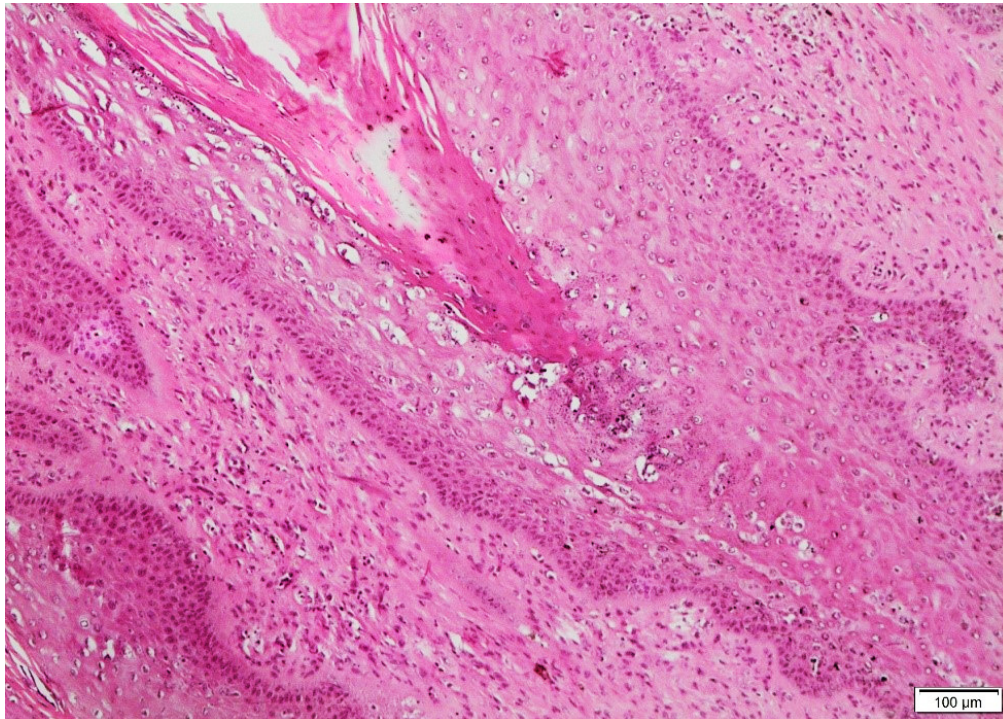


Figure 4. Dermal fibroplasia with hyperkeratosis and diffuse spongiosis in the epidermis of Holstein cows stained with hematoxylin and eosin (100 µm scale).

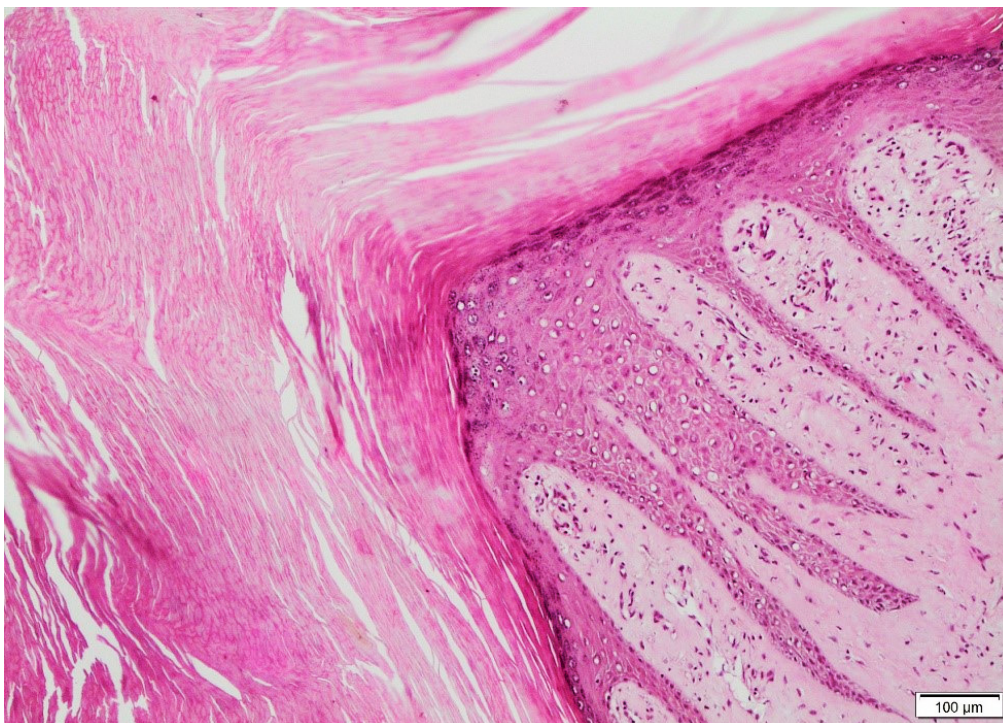


Figure 5. Holstein cow epidermal hyperkeratosis, hyperplasia, and degenerative changes (stained with hematoxylin and eosin, 100 µm scale).

Discussion

Although not very common in sheep, goats, and pigs, skin tumors are the most common tumors in cattle. It is mostly caused by papillomaviruses. Other tumor types of cutaneous and subcutaneous tissues are less common. BCP cases in cattle causes significant stress and thus loss of yield.^(5, 14, 16, 22) Although it is a self-limiting and untreated disease, because of the ability of warts to appear on or near the functional organs and the formation of infected wounds due to wart trauma or other reasons, it has to be treated. If left untreated, the permanent lesions can lead to significant loss of yield in animals due to malignant transformation to SCC or bladder transitional cells papilloma.

Hence, treatment practices are becoming more important because of all of these reasons.^(5-7, 16, 23-26) Although there have been studies on treatment, there is still a quest for a clear consensus about the final solution.^(9, 17, 27) The use of azithromycin (AZ) and a combination of trypsin, chymotrypsin, and papain proteolytic enzymes (PEC) in the treatment of BCP were not found in the scientific sources and databases. The results are important because no adverse effects of these drugs are expected, they are minimal or nule, so less labor is required in comparison with other treatment methods, and are predicted to provide faster treatment.

The aim of the study is to determine the method that can minimize this problem in the field or provide the most rapid and significant recovery without the need for surgical procedure. Medical treatment may be compulsory in some cases, especially in the case where surgical treatment is not possible due to mass localization and spread. The importance of the studies that will be applied for the treatment of patients with spontaneous BCP in the field starts here.^(17, 22) In this context, with this study, we investigated the efficacy of PEC and AZ medical treatments in spontaneous BCP cases.

Many of the studies for BCP treatment included a negative control group of 5-8 animals without any treatment to compare results.^(1, 4, 9, 10, 23) In some studies, treatment groups of 6-9 animals were compared without a control group.^(8, 13, 16, 17, 28) In this study, a negative control group ($n = 8$) was used and comparisons were made between both control and treatment groups.

In our study, BCP warts were determined in the head and neck regions consistent with different studies.^(9, 16, 17, 29) The age range of the animals was 6-17 months in our study and was also consistent with other studies.^(9, 16-17, 29-30) When the clinical findings after three months of follow up were compared assessing the complete regression of warts, the use of azithromycin appears to be more successful. When the changes in the wart numbers are examined, significant decrease was observed in the PEC group after the first month.

In group AZ, this decrease occurred at the second month. It was determined that there was a decrease in wart sizes in the controls in all animals in AZ, PEC, and CO groups. Although there was an increase in the number of warts in three animals in AZ group, two animals in CO group and an animal in PEC group, a decrease was observed later in the follow-up. These changes in 1-3 animals in each group did not create a statistically significant difference ($P > 0.05$). Cam et al.⁽¹⁰⁾ scored warts for the assessment of the treatment.

However, in our study, as in the study of Apaydin et al.,⁽²³⁾ it was preferred to calculate the decrease rates of wart counts due to heterogeneous distribution. Based on these decrease rates, treatment was found successful in both the AZ and

PEC groups. Statistically significant differences between the three groups were also stated ($P < 0.05$). When AZ and PEC groups were compared, it was found that AZ group was more successful with the decrease in wart numbers. A statistically significant difference also supports this result ($P < 0.05$).

In this study, the potential therapeutic anti-inflammatory activity of azithromycin was consistent with studies in humans and dogs.⁽²⁰⁾ It has been reported that the success rates of BCP treatments with autovaccination and autohemotherapy are about 78-100 % in some studies.^(6, 8, 12, 16, 17, 31) In spite of these effects, the fact that the preparation of the autogenous vaccine is not always possible under field conditions it increases the importance of treatment with drugs. Two other studies have reported that the use of Newcastle disease virus (NDV) vaccine and paraimmunity inducing agents provide more rapid and successful results.^(28, 32)

However, the NDV vaccine also has the disadvantage of on-site access. The paraimmunity-inducing agent was only used in two animals so there is not enough evidence of its efficacy.⁽²⁸⁾ The success rate of using ivermectin in BCP treatment was reported as 78-89,⁽⁹⁾ 87.5,⁽⁴⁾ and 100 %, ⁽³³⁾ respectively. In other similar studies, treatment success rates were reported as 70 % for *Tarantula cubensis* and 90 % for levamisole,⁽¹⁰⁾ and 93-99 % for *Paronychia kurdica*.⁽²³⁾ In the present study, according to the decrease in wart counts, the mean success rate was 92.4 % in the AZ group and 83.4 % in the PEC group. Thus, consistent results have been achieved when compared to previous medical treatment protocols that were found successful.

Conclusions

In this study, both azithromycin and a combination of proteolytic enzymes (trypsin, chymotrypsin, and papain) were shown to be effective in the treatment of bovine cutaneous papillomatosis. Moreover, these two treatment protocols were not found to have any undesirable or side effects. In addition, based on this study, the use of azithromycin in BCP treatment was found to be more effective than the combination of the proteolytic enzyme that includes trypsin, chymotrypsin, and papain. In future studies, it may be suggested to investigate the effects of these two protocols which can be used in the treatment of BCP cases in different doses in order to achieve faster treatment success. Studies on the mechanisms of action of these drugs in BCP may also be recommended.

Data availability

All relevant data are within the manuscript and the datasets generated and/or analyzed during this study are available from the corresponding author on reasonable request.

Acknowledgments

The authors thank Saban Guven for his important help in the field work and to Tuncer Kutlu for his kind help with the histopathology work. The results of this study were presented (oral) at the 2nd International Congress on Biological and Health Sciences.

Funding statement

This work was supported by the Coordinatorship of Scientific Research Projects of Hatay Mustafa Kemal University, (Project number: 17.YL.002).

Conflicts of interest

The authors have no conflict of interest to declare.

Author contributions

Conceptualization: MZY Deveci, ME Altug.

Data curation: MZY Deveci, H Alakus.

Formal analysis: MZY Deveci, H Alakus, SY Ozsoy.

Investigation: MZY Deveci, H Alakus, SY Ozsoy.

Methodology: MZY Deveci, ME Altug, SY Ozsoy.

Project administration: MZY Deveci, ME Altug.

Visualization: ME Altug.

Writing – original draft: MZY Deveci.

Writing- review and editing: MZY Deveci, ME Altug.

References

1. Archana S, Prasad A, Davis J, Seena T. Bovine papillomatosis and its treatment under farm condition. *International Journal of Current Microbiology and Applied Sciences*. 2019;8(4):2880-2884. doi: 10.20546/ijcmas.2019.804.336.
2. Jelínek F, Tachezy R. Cutaneous papillomatosis in cattle. *Journal of Comparative Pathology*. 2005;132(1):70-81. doi: 10.1016/j.jcpa.2004.07.001.
3. Olson C. Papillomaviruses. In: Z Dinter, B Morein, editors. *Virus infections of ruminants*. Amsterdam: Elsevier; 1990. pp. 189-200.
4. Kırmızıgül AH, Gökçe E, Sözmen M, Yıldırım Y, Beytuğ E. Effects of ivermectin on bovine cutaneous papillomatosis. *Kafkas Üniversitesi Veteriner Fakültesi Dergisi*. 2010;16(4):627-631. doi: 10.9775/kvfd.2009.1333.
5. Freitas A, Silva M, Jesus A, Mariz F, Cordeiro M, Albuquerque B, et al. Recent insights into bovine papillomavirus. *African Journal of Microbiology Research*. 2011;5(33):6004-6012. doi: 10.5897/AJMRX11.020.
6. Jana D, Mukherjee SK. Autogenous vaccination for management of cutaneous papillomatosis in bovines. *Intas Polivet*. 2015;16(2):414-417.
7. Ugochukwu ICI, Aneke CI, Idoko IS, Sani NA, Amoché AJ, Mshiela WP, et al. Bovine papilloma: aetiology, pathology, immunology, disease status, diagnosis,

- control, prevention and treatment: a review. *Comparative Clinical Pathology*. 2019;28:737-745. doi: 10.1007/s00580-018-2785-3.
8. Biricik HS, Keskin O, Cimtay I, Baba ZF. Comparison of autogenous vaccine and autohaemotherapy administrations in the treatment of bovine papillomatosis. *Turkish Journal of Veterinary and Animal Sciences*. 2003;27(3):703-707.
 9. Bökü MK, Atalay O, Kibar M, Çam Y, Atasever A. Ivermectin is an effective treatment for bovine cutaneous papillomatosis. *Research in Veterinary Science*. 2007;83(3):360-363. doi: 10.1016/j.rvsc.2007.01.016.
 10. Cam Y, Kibar M, Atasever A, Atalay Ö, Beyaz L. Efficacy of levamisole and *Tarantula cubensis* venom for the treatment of bovine cutaneous papillomatosis. *Veterinary Record*. 2007;160(14):486-488. doi: 10.1136/vr.160.14.486.
 11. Gourreau J, Bendali F. The papillomatosis. In: F Agricole, editor. *Diseases of cattle*. 4th ed. Paris: Institut de L'élevage; 2008. pp. 376-379.
 12. Jarrett W, O'Neil B, Gaukroger J, Smith K, Laird H, Campo MS. Studies on vaccination against papillomaviruses: the immunity after infection and vaccination with bovine papillomaviruses of different types. *Veterinary Record*. 1990;126(19):473-475. doi: 10.1136/vr.126.19.473.
 13. Kavithaa N, Rajkumar NV, Jiji R. Papillomatosis in jersey cows and its different medical treatment. *International Journal of Science, Environment and Technology*. 2014;3(2):692-694.
 14. Mates N, Muste A, Oana L, Meculoiu D. Observations on papillomatosis in animals. *Revista Romana de Medicina Veterinaria*. 1994;4:363-368.
 15. Ssenyonga G, Onapito J, Nakasala-Situma J, Omara-Opyene A. Therapeutic value of partial excision of lesions combined with administration of an autogenous vaccine during an episode of cutaneous papillomatosis in cattle of Uganda. *Journal of the American Veterinary Medical Association*. 1990;197:739-740.
 16. Terziev G, Roydev R, Kalkanov I, Borissov I, Dinev I. Papillomatosis in heifers—comparative studies on surgical excision and autogenous vaccine therapies. *Trakia Journal of Sciences*. 2015;13:274-279. doi: 10.15547/tjs.2015.s.02.061.
 17. Cimtay I, Biricik H, Keskin O, Baba Z. Comparative studies on the efficacy of different vaccination methods in the treatment of bovine papillomatosis. *Turkish Journal of Veterinary and Animal Sciences*. 2003;27:929-933.
 18. Munday J, Cullum A, Thomson N, Bestbier M, McCormack T, Julian AF. Anal fibropapillomas containing bovine papillomavirus type 2 DNA in two groups of heifers. *New Zealand Veterinary Journal*. 2018;66(5):267-271. doi: 10.1080/00480169.2018.1479317.
 19. Atasoy M, Ozdemir S, Aktas A, Aliagaoglu C, Karakuzu A, Erdem T. Treatment of confluent and reticulated papillomatosis with azithromycin. *The Journal of Dermatology*. 2004;31:682-686. doi: 10.1111/j.1346-8138.2004.tb00577.x.
 20. Yagci BB, Ural K, Ocal N, Haydardedeoglu AE. Azithromycin therapy of papillomatosis in dogs: a prospective, randomized, double-blinded, placebo-controlled clinical trial. *Veterinary Dermatology*. 2008;19:194-198. doi: 10.1111/j.1365-3164.2008.00674.x.
 21. Aytekin O. Uses of proteolytic enzymes on treatment and effects on cow's mastitis treatment. *Van Veterinary Journal*. 2016;27(1):43-47.
 22. Salib FA, Farghali HA. Clinical, epidemiological and therapeutic studies on bovine papillomatosis in Northern Oases, Egypt in 2008. *Veterinary World*. 2011;4:53. doi: 10.5455/vetworld.2011.53-59.

23. Apaydin A, Aydin M, Ciftci O, Timurkaan N, Yildiz H, Tonbak S. Effects of *Paronychia kurdica* on teat and udder papillomatosis in cows. *Revue de Médecine Vétérinaire*. 2010;161(6):267-271.
24. Tan MT, Yildirim Y, Sozmen M, Dagalp SB, Yilmaz V, Kirmizigul AH, et al. A histopathological, immunohistochemical and molecular study of cutaneous bovine papillomatosis. *Kafkas Üniversitesi Veteriner Fakültesi Dergisi*. 2012;18(5):739-744. doi: 10.9775/kvfd.2012.5341.
25. Nicholls PK, Stanley MA. The immunology of animal papillomaviruses. *Veterinary Immunology and Immunopathology*. 2000;73:101-127. doi: 10.1016/S0165-2427(99)00165-8.
26. Step DL, Streeter RN, Confer AW, Kirkpatrick JG, Sundberg JP, Arnold CS, et al. Urinary bladder transitional cell papilloma in a shorthorn heifer. *The Canadian Veterinary Journal*. 2000;41(10):794.
27. Hemmatzadeh F, Fatemi A, Amini F. Therapeutic effects of fig tree latex on bovine papillomatosis. *Journal of Veterinary Medicine, Series B*. 2003;50(10):473-476. doi: 10.1046/j.1439-0450.2003.00702.x.
28. Turk N, Zupancic Z, Staresina V, Kovac S, Babic T, Kreszinger M, et al. Severe bovine papillomatosis: detection of bovine papillomavirus in tumour tissue and efficacy of treatment using autogenous vaccine and paramunity inducer. *Veterinarski Arhiv*. 2005;75(5):391-397.
29. Atasever A, Cam Y, Atalay O. Skin papillomatosis in a cattle herd. *Ankara Üniversitesi Veteriner Fakültesi Dergisi*. 2005;52:197-200.
30. White SD. Diseases of the skin. In: BP Smith, editor. *Large Animal Internal Medicine*. 5th ed. St. Louis: Elsevier Mosby; 2015. pp. 1202-1204.
31. Lesnik F, Bires J, Suli J, Korim P, Posivak J, Mattova J, et al. Autovaccination and metabolic profiles at bovine papillomatosis. *Slovensky Veterinarsky Casopis*. 1999;24:290-294.
32. Avki S, Turutoglu H, Simsek A, Unsal A. Clinical and immunological effects of Newcastle disease virus vaccine on bovine papillomatosis. *Veterinary Immunology Immunopathology*. 2004;98(1-2):9-16. doi: 10.1016/j.vetimm.2003.10.003.
33. Jana D, Mukherjee SK. Management of bovine cutaneous papillomatosis with ivermectin in farm bred calf crops of West Bengal. *The Indian Journal of Veterinary Sciences and Biotechnology*. 2012;8(01):69-71.